

PROPATH

THE FOCUS

Immunohistochemistry

Immunohistochemistry in dermatofibrosarcoma protuberans (DFSP) vs. dermatofibroma-fibrous histiocytoma (DF-FH)

March 2005

by Rodney T. Miller, M.D., Director of Immunohistochemistry

Although many times the distinction of dermatofibroma (a.k.a. fibrous histiocytoma) (DF-FH) from dermatofibrosarcoma protuberans (DFSP) is relatively easy to make on H&E, in some cases it can be difficult. Obviously, accurate diagnosis is important, since the natural history and treatment of DFSP differs greatly from that of DF-FH. In these situations, immunohistochemistry can be of great value in arriving at the correct diagnosis. This month, we briefly review markers that can be of utility in approaching this differential diagnosis.

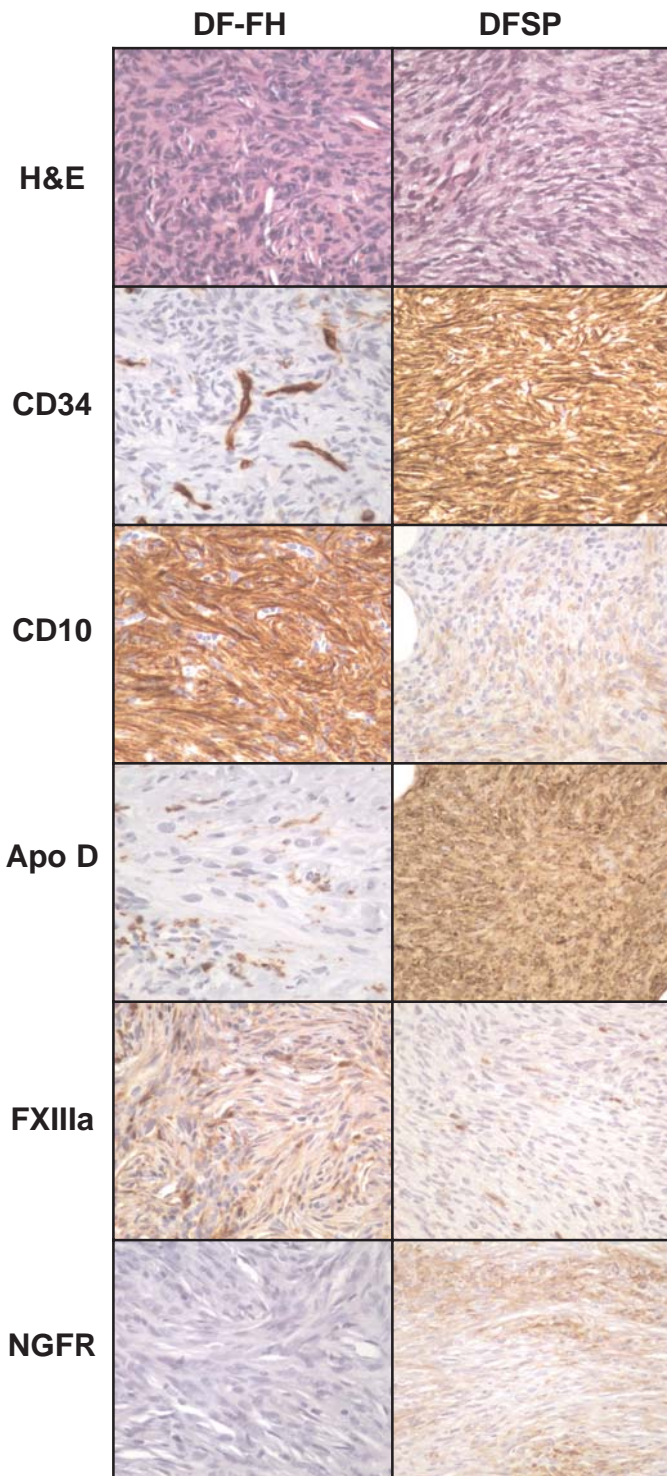
Undoubtedly the most commonly employed marker for DF-FH vs. DFSP is **CD34**. DFSP characteristically expresses CD34 in a strong and diffuse fashion. In contrast, DF is usually negative or weakly positive for CD34. However, very commonly DF-FH's may show substantial CD34 reactivity at the periphery of the lesion, but the central portion characteristically shows substantially less reactivity. As such, this point must be kept in mind when faced with a tiny or questionably adequate biopsy. An additional important point to know is that CD34 is certainly not specific for DFSP, as many skin lesions may express this antigen. In certain situations normal or reactive skin may also have numerous CD34-positive cells in the background. Therefore, CD34 reactivity in a spindle cell lesion of the skin supports DFSP only in the appropriate morphologic background.

An additional promising marker for this differential diagnosis is **CD10**, as reported in a 2000 paper in *Anticancer Research*. DF's typically have strong dif-

fuse CD10, in contrast to DFSP's, that demonstrate much weaker and patchier expression of this antigen.

In the August 2004 edition of *The American Journal of Surgical Pathology*, a report described the utility of immunostains for Apolipoprotein D (**Apo D**) for the recognition of DFSP. By studying large numbers of soft tissue tumors using gene microarray profiling, the authors found that DFSP was characterized by high expression of Apo D. They subsequently prepared a tissue microarray containing 421 soft tissue tumors and stained it for ApoD. Nine of the 10 DFSP's showed strong expression of Apo D, and this marker was absent in 16 typical DF-FH's and an additional 12 variants (angiomatoid, epithelioid, plexiform, aneurysmal, and atypical). In addition to classic DFSP, Apo D was strongly expressed in Bednar tumor, 2 of 3 cases of giant cell fibroblastoma, 6 of 8 neurofibromas, 2 of 2 alveolar soft part sarcomas, and several miscellaneous other tumors.

Factor XIIIa is another marker that can be of utility. DF-FH often has numerous Factor XIIIa-positive macrophages in the background, in contrast to DFSP. Unfortunately, the polyclonal Factor XIIIa antibody that we had used for many years is no longer available (the rabbit died), and I have been unable to find another replacement Factor XIIIa antibody (either polyclonal or monoclonal) that provides me with the sensitive and specific results that I am used to seeing. As such, in my own practice, this particular antibody is not nearly as useful to me as it has been in the past.



High power photomicrographs of H&E and immunostains from a typical DF (left column) and DFSP (right column).

	CD34	CD10	Apo D	FXIIIa	NGFR
DF-FH	neg or weak +	strong +	neg or weak +	many +cells	neg or weak +
DFSP	strong +	neg or weak +	strong +	few +cells	mod-strong +

Expected immunostain results in "classic" cases of DF-FH and DFSP

Alas, nothing is ever perfect, including the border between DFSP and DF-FH. Some authors have described tumors that have indeterminate or overlapping features between DF-FH and DFSP, and indeed we have seen several of these cases at ProPath over the past few years.

In most cases, the distinction of DF-FH from DFSP can be made with 1 or 2 immunostains, depending on the particular pathologist's preferences. I usually start with CD34 and CD10 or ApoD and CD10, and progress to other markers if needed.

All of the markers discussed above are available at the ProPath Immunohistochemistry Laboratory.

REFERENCES:

West RB et al: Apo D in soft tissue tumors. A novel marker for dermatofibrosarcoma protuberans. Am J Surg Pathol 28(8): 1063-1069, Aug 2004.

Kanitakis J et al: Expression of the CD10 antigen (neutral endopeptidase) by mesenchymal tumors of the skin. Anticancer Res 20(5B): 3539-3544, Sep-Oct 2000.

Miettinen M: Diagnostic soft tissue pathology. Churchill-Livingstone, New York, 2003, page 56.

Horenstein M et al: Indeterminate fibrohistiocytic lesions of the skin. Is there a spectrum between dermatofibroma and dermatofibrosarcoma protuberans? Am J Surg Pathol 24(7): 996-1003, 2000.

Rodney T. Miller, M.D.

Director of Immunohistochemistry
 214-237-1631 • Fax 214-237-1770
 rmiller@propathlab.com

Prior Editions are available for download on our Web site.



8267 Elmbrook Dr, Ste 100 • Dallas, Texas 75247-4009
 (214) 638-2000 • Fax: (214) 905-3457
 www.propathlab.com

Some authorities (Miettinen) have written that nerve growth factor receptor (**NGFR**) can be useful to distinguish DFSP (positive for NGFR) from DF-FH (negative for NGFR), although I have not found this to be particularly useful in my practice.